

# IMPACT OF PREOPERATORY MAGNETIC RESONANCE IMAGING IN ONCOPLASTIC SURGERY

## Impacto da ressonância magnética pré-operatória na cirurgia oncoplástica

Karina Furlan Anselmi<sup>1\*</sup>, Cicero Urban<sup>1</sup>, Linei Urban<sup>2</sup>, Ana Paula Martins Sebastião<sup>1</sup>, Rubens Lima<sup>1</sup>, Flavia Kuroda<sup>1</sup>, Cleverton Spautz<sup>1</sup>, Thiago Astorga Martins<sup>1</sup>, Iris Rabinovich<sup>1</sup>, Eduardo Schunemann<sup>1</sup>

### ABSTRACT

**Objective:** There is no data about magnetic resonance image (MRI) impact in oncoplastic surgery (OP). The objective of this study was to evaluate the impact of MRI on the surgical planning and the changes of conduct in patients with initial breast cancer and candidates to perform the OP. **Methods:** This is a prospective cohort of 60 patients who were candidates to OP between January 2013 and July 2014. All of them underwent to a preoperative MRI, in addition to mammography (MG) and ultrasound (US). Any additional tumor in the MRI classified as BIRADS 4-5 were biopsied or marked with carbon and radiotracer in order to be localized during the surgery. Surgical impact of additional MRI findings were evaluated as to changes of approach to mastectomy or to wider resection. **Results:** Of the patients, 29/60 (48.3%) had additional findings on MRI, 16/29 (55%) were multifocal tumors, 1/29 (3.4%) was multicentric, 5/29 (17%) were contralateral tumors, and 9/29 (31%) presented tumor size larger than 10 mm in the MRI. Of 22 patients who showed additional lesions on MRI, 15 (68.2%) had invasive carcinomas in the definitive anatomopathological exam. Sensibility of MRI was higher in the estimation of the tumor size. Of the patients, 12/60 (20%) underwent to mastectomy, and 17/60 (28.3%) to wider resections. Only 5% of patients had positive margins in the entire group, and in the group of patients that had additional findings on MRI only 3.4% had positive margins. **Conclusions:** MRI is better than MG and US in evaluating the extension of the tumor, and in the detection of multicentricity, multifocality and bilaterality. In consequence, it contributed in this series for a better surgical planning in OP with a low rate of compromised margins and re-operations.

**KEYWORDS:** Breast cancer; magnetic resonance imaging; surgery.

### RESUMO

**Objetivo:** Não há dados sobre o impacto da imagem de ressonância magnética (RM) na cirurgia oncoplástica. O objetivo deste trabalho foi avaliar o impacto da RM no planejamento cirúrgico e nas mudanças de conduta em pacientes com câncer de mama inicial e candidatas a realizar a cirurgia oncoplástica. **Métodos:** Trata-se de uma coorte prospectiva de 60 pacientes que foram candidatas à cirurgia oncoplástica entre janeiro de 2013 e julho de 2014. Todas elas foram submetidas a uma RM pré-operatória, além de mamografia (MG) e ultrassom (US). Qualquer tumor adicional na RM classificada como BIRADS 4-5 foi biopsiado ou marcado com carvão e ROLL para serem localizados durante a cirurgia. O impacto cirúrgico dos achados adicionais da RM foi avaliado quanto a mudanças para mastectomia ou ressecção mais ampla. **Resultados:** Das pacientes, 29/60 (48,3%) apresentaram achados adicionais na ressonância magnética, 16/29 (55%) foram tumores multifocais, 1/29 (3,4%) foi multicêntrico, 5/29 (17%) foram tumores contralaterais e 9/29 (31%) apresentaram tamanho de tumor maior que 10 mm na RM. Das 22 pacientes que apresentaram lesões adicionais na RM, 15 (68,2%) apresentaram carcinomas invasivos no exame anatomopatológico definitivo. A sensibilidade da RM foi maior na estimativa do tamanho do tumor. Das pacientes, 12/60 (20%) foram submetidas à mastectomia e 17/60 (28,3%) a ressecções mais amplas. Apenas 5% das pacientes apresentaram margens positivas em todo o grupo. No grupo de pacientes que apresentaram resultados adicionais na RM, apenas 3,4% tiveram margens positivas. **Conclusões:** A RM é melhor que a MG e o US na avaliação da extensão do tumor e na detecção de tumores multicêntricos, multifocais e bilaterais. Em consequência, contribuiu nesta série para um melhor planejamento cirúrgico na cirurgia oncoplástica com baixa taxa de margens comprometidas e reexecução.

**PALAVRAS-CHAVE:** Câncer de mama; imagem por ressonância magnética; cirurgia.

Study carried out at Unidade de Mama do Hospital Nossa Senhora das Graças – Curitiba (PR), Brazil.

<sup>1</sup>Unidade de Mama, Hospital Nossa Senhora das Graças – Curitiba (PR), Brazil.

<sup>2</sup>Clínica de Diagnóstico Avançado por Imagem, DAPI – Curitiba (PR), Brazil.

\*Corresponding author: kfurlan@terram.com.br

Conflict of interests: nothing to declare.

Received in: 05/14/2017. Accepted in: 05/29/2017

## INTRODUCTION

Mastectomy was considered the standard treatment for oncoplastic surgery (OP) until the early 1970s, when randomized clinical trials showed equivalence in terms of long-term survival and local control of the disease with breast-conserving treatment (BCT)<sup>1,2</sup>. However, BCT has shown high re-operation rates in some recent series<sup>3,4</sup>. Thus, accuracy on the local preoperative staging is considered essential for better planning the techniques that should be applied in each individual case. Clinical exam, mammography (MG) and ultrasound (US) correspond to the triad traditionally used for this end.

OP combines the principles of plastic surgery with those of surgical oncology, and represents quite an advance in BCT<sup>5</sup>. The aim of it is to preserve the quality of life of patients with surgeries that can be efficient from the oncologic point of view without compromising the aesthetic-functional outcomes. Besides that, it reduces the risk of compromised margins, when compared to traditional BCT techniques. Nevertheless, accuracy of imaging methods is essential to the surgical planning, mainly concerning the choice of pedicles, incisions and techniques for symmetry in the contralateral breast.

Several studies have shown the high sensitivity of magnetic resonance (MRI) to evaluate tumor extension, multifocality and multicentricity<sup>6-34</sup>. However, there are some controversies concerning the application of MRI as a method of preoperative staging in BCT, as it increases eligibility to mastectomies. In addition, some criticism toward the preoperative MRI use in the routine of BCT sustain that many of the additional lesions might not have any clinical or biological relevance, or even that they could be treated in a more effective way through radiotherapy instead of more aggressive surgeries<sup>35</sup>.

Therefore, this study aimed to evaluate the sensitivity, specificity and the impact of MRI on surgical planning in patients with breast cancer eligible to OP.

## METHODS

Sixty patients were included in this prospective single-arm cohort study. All of them had invasive breast cancers T1-T2, or ductal carcinoma in situ (DCIS), with the age ranging between 25 and 80 years old. All patients were evaluated and diagnosed through clinical exam, MG, US and breast biopsy (core-biopsy or vacuum-assisted biopsy). They were clinically eligible to undergo BCT with OP techniques at the Breast Unit of Hospital Nossa Senhora das Graças (HNSG) in Curitiba (Brazil) between January 2013 and July 2014. After the diagnosis, the patients underwent MRI. All results were evaluated by the same radiologist (LU), who has full dedication to breast imaging and ten years of experience in breast MRI. Additional lesions at MRI classified as BIRADS 3 were not considered for surgical resection. Such patients were followed-up every six months for a period of two years, whenever the lesion has

not been resected in the mammoplasty area. Additional lesions detected in MRI classified as BIRADS 4 were biopsied or marked both with radioactive tracer and carbon under MRI guidance or had a second-look on the US, then resected during the surgery. BIRADS 5 lesions were biopsied during the preoperative stage. In order to be included in this study, additional lesions detected through MRI had to be as large as, or larger than, 5 mm.

Patients excluded from this study were those with locally advanced or metastatic disease at initial diagnosis, those who underwent MRI prior to the diagnosis, those who chose mastectomy despite being eligible to BCT, those undergoing neoadjuvant chemotherapy, those who had previous oncological treatment for other cancers, and those with contraindication or allergy to the MRI contrast or claustrophobia.

## Magnetic Resonance Imaging

MRI exams were performed with a 1.5 T (Avanto®, Siemens) equipment, having patients in prone position, with a 16-channel RF coil. The contrast used had a dose of 0.2 mL/Kg Omniscan® (Gadolineo, GE Healthcare), with a 3 mL/s infusion pump. Other exam protocols included pondered sequences in T2 (axial plane) and STIR (sagittal plane), followed by a 3D dynamic sequence pondered in T1 with a fat saturation (axial), and immediate reconstruction with subtraction (one pre-contrast sequence and four post-contrast sequences, at a rate of 90 seconds/acquisition and 7 minutes total time). The dynamic sequence was followed by a high-resolution 3D acquisition pondered in T1 with fat saturation (sagittal) for reconstruction. After that, all exams were sent to a workstation (Carestream Health), where the radiologist evaluated the morphology and the dynamic behavior of the lesions, classifying them according to the current BI-RADS® system. All additional lesions underwent a second-look ultrasound and, once any abnormality was found, a core-biopsy was also performed. In case no abnormality was found in the second-look ultrasound, they underwent percutaneous vacuum-assisted biopsy (Mamotomme®) or preoperative marking with radiotracer and activated carbon 4% guided through MRI (Breast Biopsy®, Avanto, Siemens). All mammograms and ultrasounds were reviewed by the same radiologist (LU), in order to compare them to the MRI.

## Pathology

A pathologist fully dedicated to breast pathology (APMS) did at least three methods for intraoperative margins and sentinel node assessment: gross, touch imprint and frozen sections. Each surgical specimen had their margins properly marked by the surgical team with colored buttons, and with complete radiological and clinical data information. The whole specimen had been inked and thinly sliced. Margins were considered negative when cancer cells do not touch inked surface. The tumor size measurements for the final report were assessed on gross for

tumors larger than 20 mm and through microscopy for tumors smaller than 20 mm. Additional lesions detected through MRI (all of them marked with carbon) were evaluated by the pathologist as to their size and whether they were invasive carcinoma or DCIS, or even benign or atypical lesions.

### Oncoplastic surgery techniques

The OP techniques used in this series were: inferior and superior pedicle, and round-block. In cases in which the surgical plan changed to mastectomy, patients underwent skin-sparing mastectomy or nipple-sparing mastectomy, according to the risk of compromising nipple and areola complex, with immediate reconstruction with definitive form-stable anatomical implants.

### Statistical analysis

In order to analyze whether the differences between tumor sizes, measured by means of three distinctive methods (MRI, US and MG), were representative, a Friedman's test with a posteriori Dunn's test was applied. Besides that, in order to check if the tumor size measured through the anatomopathological exam after the surgery was different from the one measured on the MRI, a Wilcoxon's test was used. In order to analyze the association between a change of approach by the patient and the tumor size on the MRI and on the anatomopathological exam, as well as the association between a change of approach and the several variables, a Mann-Whitney's test was applied; also the  $\chi^2$  distribution or Fisher's exact test was applied, depending on whether the variable was quantitative or qualitative. The same tests were used in order to evaluate the association between the change of approach in the group of women with additional lesion, as well as in the group of women that underwent mastectomy, after taking MRI. Non-parametrical analyses were used whenever the variables studied failed Shapiro-Wilk's normality test. The statistical analyses was performed with GRAPHPAD PRISM's statistical package, which is considered as level of significance at 5% ( $\alpha=0.05$ )<sup>36,37</sup>.

### Ethical aspects

This study was approved by the Internal Review Board from Positivo University.

## RESULTS

Sixty patients were included in this prospective cohort. The characteristics of the population can be found in Table 1. Twenty-nine (48.3%) patients showed additional findings considered suspect for malignancy in the same breast or in the contralateral breast, and/or tumor size larger than the one studied on the MG and on the US, exceeding 10 mm of difference on MRI (Table 2). Among the additional findings in the MRI, 16/29 (55.2%) were multifocal tumors, 1/29 (3.4%) were multicentric

**Table 1.** Characteristics of the patients eligible to oncoplastic surgery and undergoing preoperative magnetic resonance imaging.

Characteristics	n (%)
Age – in years	54.7±10.6
Menopausal condition	
Pre-menopause	24 (40.0)
Post-menopause	36 (60.0)
Family history	
Positive	10 (16.7)
Negative	50 (83.3)
T	
Tis	2 (3.1)
T1	44 (67.7)
T2	19 (29.2)
BMI	
Underweight	1 (1.6)
Normal weight	27 (45.0)
Overweight	20 (33.0)
Obesity	12 (20.0)
Breast size	
Small	7 (11.7)
Medium	22 (36.7)
Large/Extra large	31(51.7)
Histological type	
Ductal invasive carcinoma	36 (60%)
Ductal carcinoma in situ	3 (5.0)
Lobular invasive carcinoma	13 (21%)
Others	8 (13%)
Angiolymphatic invasion	
Present	18 ( 30.5)
Absent	42 (69.5)
N	
0	44 (78.0)
1	13 (22.0)
Estrogen receptor	
Positive	53 (89.8)
Negative	7 (10.2)
Progesterone receptor	
Positive	49 (81.4)
Negative	11 (18.6)
HER2	
Positive	6 (10.2)
Negative	54 (89.8)
Not researched	4 (6.2)
Ki67	
<15%	35 (58.4)
>15%	25 (41.6)

BMI: Body Mass Index; T: Primary tumor size; N: Regional lymph nodes metastasis; HER2: Human Epidermal growth factor receptor 2; Ki67: Antigen KI-67.

tumors, 5/29 (17.2%) were tumors in the contralateral breast, and 9/29 patients (31.0%) had tumors sized larger than 10 mm on MRI, when compared with the MG and the US (Table 2). The MRI had higher sensibility to estimate the tumor size, when compared to the definitive anatomopathological exam, both on the comparison with tumors that could only be seen through MG or US and, in the same way, with those which were found through both MG and US (Table 3).

In the group that had additional lesions or differences in tumor size above 10 mm on MRI, the following results were found: 18/29 (62.1%) invasive ductal carcinomas, 5/29 (17.2%) invasive lobular carcinomas, 3/29 (10.3%) DCIS, 2 (6.9%) mucinous invasive carcinomas, and 1 (3.4%) tubular invasive carcinoma. As the secondary variables (age, body mass index (BMI), family history, menopausal condition, presence of angiolymphatic invasion and Ki 67>15%) were analyzed, no representative association between such variables and the detection of additional findings in MRI was found. When the tumors were classified as luminal, A, B, HER2 and triple negative, none of them was statistically significant for findings of additional lesions or for different tumor size on the MRI. All suspect additional tumors in MRI were marked with activated carbon and were localized on the definitive anatomopathological exam. Thus, from the 22 patients that showed additional lesions,

15 (68.2%) had invasive carcinomas confirmed through the anatomopathological exam.

From the 29 patients who showed additional lesions in MRI or tumor size exceeding 10 mm on the MRI, 12 (41.3%) had a change of approach to mastectomy, and 17 (58%) had larger resection using OP techniques, keeping the conservative approach. Twelve patients among the population studied (12/60) (20%) underwent mastectomy due to MRI findings, out of whom 3 (25%) underwent nipple-sparing mastectomy, 6 (50%) underwent skin-sparing mastectomy, 1 (8.3%) underwent bilateral skin-sparing mastectomy, and 2 (16.6%) underwent bilateral nipple-sparing mastectomy. Bilaterality appeared in 5% of the patients in this series, and it was detected only through MRI. Patients who underwent a better surgical planning for the conservative surgery were 17/60 (28.3%), with larger resections and immediate reconstruction using OP techniques, aiming to encompass the

**Table 2.** Additional results found only through magnetic resonance imaging in 60 patients with breast cancer eligible to oncoplastic surgery.

Additional finding through MRI	n (%)
Multifocality	16 (26.7)
Multicentricity	1 (1.7)
Difference in TS >10 mm when compared to MG and US	9 (15)
Tumor in the contralateral breast	5 (8.3)

MRI: magnetic resonance imaging; MG: mammography; US: ultrasound; TS: tumor size.

**Table 3.** Comparison of tumor size between magnetic resonance imaging, mammography, ultrasound and definitive anatomopathological exam in patients eligible to oncoplastic surgery.

Comparison between MRI and MG (n=41)		
Concordance	34 (82.9%) vs 25 (61.0%)	p=0.033
Underestimated	2 (4.9%) vs 10 (24.4%)	
Overestimated	5 (12.2%) vs 6 (14.6%)	
Comparison between MRI and US (n=53)		
Concordance	48 (90.5%) vs 38 (71.7%)	p=<0.001
Underestimated	2 (3.8%) vs 15(28.3%)	
Overestimated	3 (5.7%) vs 0	
Comparison between MRI and MG+US (n=60)		
Concordance	53 (88.4%) vs 42 (70%)	p=0.014
Underestimated	2 (3.3%) vs 12 (20.0%)	
Overestimated	5 (8.3%) vs 6 (10%)	

MRI: Magnetic Resonance Imaging; MG: mammography; US: ultrasound.

**Table 4.** Correlation between additional findings through magnetic resonance imaging and changes in surgical approach for patients eligible to oncoplastic surgery.

	Wider resection	Mastectomy	Contralateral mastectomy	Contralateral resection
Difference in TS> 10 mm on MR	8	1	0	0
Multicentricity	0	1	0	0
Multifocality	8	8	0	0
Contralateral breast lesion	0	0	3	2
Breast size				
S	1	3	1	0
M	3	4	2	1
L	11	2	0	1

TS: tumor size; MRI: magnetic resonance imaging; S: small; M: medium; L: large.

multifocal lesions or enlarging the resection for in case of patients that showed tumor size larger than 10 mm on the MRI (Table 4). Secondary variables, such as BMI, breast size, age, menopause, Ki 67>15%, family history, presence of angiolymphatic invasion and presence of positive sentinel lymph node, had no association with this group. When classified as luminal A, B, HER2 and triple negative, none of them was statistically significant too.

Among the 12 patients who underwent mastectomy, the eligibility to this procedure was due to the fact that, in 10 of them (83%) the lesions were multifocal, in 1 (8.3%) it was multicentric, and in 3 (25%) cancer in the contralateral breast was detected through MRI. As to tumor size, 6 (50%) patients who underwent mastectomy had tumors larger than 20 mm on the MRI exam. Considering the secondary variables among these patients, 4 (33.0%) had small size breasts, 6 (50%) had medium size breasts and 2 (16%) had large size breasts. As to family history, 5 (41.0%) of them had positive family history on the first-degree relatives for breast cancer. From the 12 mastectomies performed, 10 (83.3%) were considered eligible due to the lack of proportion between the breast size and the tumor size, added to the presence of multifocality and/or multicentricity, as well as positive family history (Table 5).

Only 3/60 (5%) patients had positive margins in the entire group, 3/48 (6.2%) exclusively in OP group, and in the group of 29 patients that had additional lesions on the MRI or tumor size larger than 10 mm on the MRI, only 1 (3.4%) had positive margins. The 2 patients that did not have additional lesions on the MRI and had positive margins were re-operated with OP techniques, and the only patient that had additional findings and positive margins was also re-operated with OP techniques (Figure 1). All of them had free margins and kept the conservative approach.

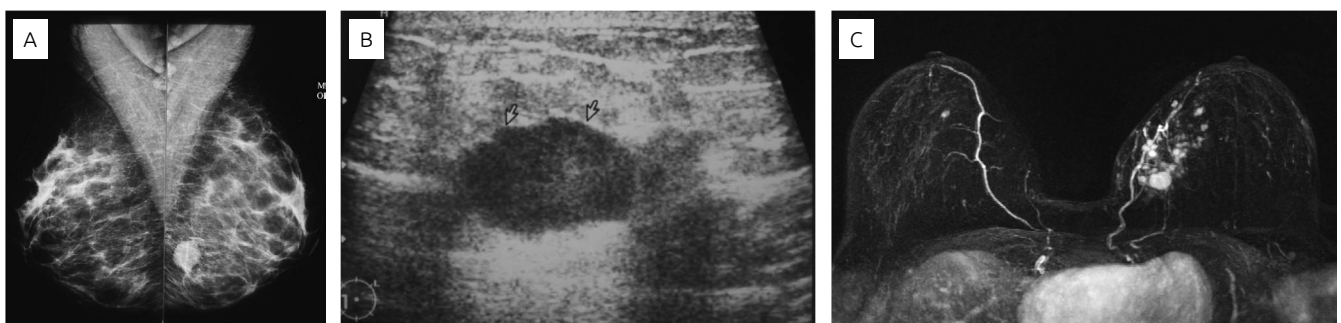
## DISCUSSION

There are several studies comparing MRI with MG and US on the preoperative staging of patients with breast cancer. In most of them, the aim was to evaluate the MRI accuracy in the estimation

**Table 5.** Risk clinical findings leading to mastectomy in patients eligible to conservative surgery who underwent magnetic resonance imaging in the preoperative stage.

Variable	Mastectomy		P
BMI (kg/m <sup>2</sup> )			
Yes (n=12)	25.1±3,9		0.115
No (n=48)	27.6±5,2		
Age > 50 years			
Yes (n=34)	5	29	0.3319
No (n=26)	7	19	
Family history			
Yes (n=10)	5	5	0.021
No (n=50)	7	43	
Breast size			
Small (n=7)	4	3	0.016
Medium (n=22)	6	16	
Large (n=31)	2	29	
Menopause			
Yes (n=36)	5	31	0.1932
No (n=24)	7	17	
Ki67 > 15%			
Yes (n=26)	7	19	0.3358
No (n=33)	5	28	
AL invasion			
Yes (n=18)	6	12	0.156
No (n=41)	6	36	
Positive LS			
Yes (n=13)	3	10	0.711
No (n=46)	9	38	
Molecular classification			
HER2 (n=5)	2	3	0.556
Luminal A (n=32)	5	28	
Luminal B (n=19)	4	15	
Triple Negative (n=3)	1	2	
Tumor size AP			
T1	8	36	0.716
T2	4	12	

BMI: Body Mass Index; AL: Angiolymphatic invasion; LS: Sentinel lymph node; AP: Pathology; HER2: Human Epidermal growth factor receptor 2; Ki67: Antigen KI-67.



**Figure 1.** Example of a patient with distinct findings on mammogram, ultrasound and magnetic resonance imaging: (A) well delimited breast mass, BIRADS 0 on mammogram; (B) solid mass, with indistinct margins, BIRADS 4; (C) additional tumors on magnetic resonance imaging in the same breast (multifocal tumor), and contralateral tumor, BIRADS 6.

of tumor extension and diagnosis of additional tumors in the same breast and/or in the contralateral one. Though none of them evaluated the MRI impact in OP, which is such an approach that allows to do larger resections in BCT<sup>5-34</sup>.

In this prospective study, a rate of 48% (29/60) of additional findings was identified. The rates of multifocality, multicentricity and contralateral breast lesions in the 60 patients of our series were 26.7, 1.7 and 8.3% respectively. Houssami and Hayes, in a series with 2,610 patients, detected 40% of multifocal and multicentric tumors<sup>31</sup>. COMICE trial detected 16% of multifocal tumors<sup>13</sup>. The contralateral tumor rates found in our series were similar to other series<sup>23,27-29</sup>.

From the additional lesions suspect of malignancy detected through MRI, 68% were positive on the anatomopathological exam. This is closer to the meta-analysis by Houssami et al., in which it was found 66%<sup>21</sup>. From the analyses of multifocal lesions, 58% were confirmed as malignant in the anatomopathological exam. The multicentric lesions and the lesions detected in the contralateral breast through MRI were 100% malignant in the anatomopathological exam.

It is not known whether additional tumors detected on MRI could be treated exclusively with adjuvant radiotherapy<sup>31-33,35</sup>. So, several studies reported a rate of change of surgical plan to mastectomy or to wider resections between 8.3 and 43%<sup>18,19,23,24,28,30</sup>. To our knowledge, this is the first study that refers to the impact of MRI on OP patients. After preoperative MRI, 20% of mastectomies and 80% of OP were performed in this group. And, among them, 28% had larger resections aiming to encompass multifocal lesions or larger tumors detected on MRI. In 52% of patients, the MRI had no impact on surgical decisions.

From 12 mastectomies in this series, 10 (83.3%) were due to the lack of proportion between the breast size and tumor size,

added to the presence of multifocality and/or multicentricity, as well as positive family history. So, patients were referred to mastectomy not only due to the suspect additional findings on MRI. But, even for these cases, all patients had mastectomy skin-sparing or nipple-sparing with immediate breast reconstruction.

Considering the lesions that had over 10 mm in MRI, when compared to MG and US, the results were comparable to those found by Pengel et al.<sup>19</sup>. These authors demonstrated that the extension of tumor size is larger on MRI than on MG and US, as well as on the two associated exams. However, tumor size in MRI is more accurate when compared to definitive anatomopathological exam. Van Goethem et al. concluded that MG underestimates tumor size in 37%<sup>20</sup>. Our study confirmed that MG underestimated lesion size in 24% and that US did it in 28%.

The rates of positive margins and re-excisions were low in this series. From the 60 patients included here, the rate of positive margins was 5%, 6.2% in OP group (excluding patients who underwent mastectomy), and 3.4% in patients with additional findings on MRI.

## CONCLUSION

There is still controversy with MRI in preoperative planning in breast cancer patients. However, the findings of this study have shown that MRI is more accurate than mammography and US in evaluating the extension of the tumor, in the detection of multicentricity, multifocality and bilaterality, thus contributing for a better surgical planning in OP. The consequence of that was a low rate of re-operations. Prospective and randomized trials are needed to confirm such findings.

## REFERENCES

1. Veronesi U, Cascinelli N, Mariani L, Greco M, Saccozzi R, Luini A, et al. Twenty-year follow-up of a randomized study comparing breast-conserving surgery with radical mastectomy for early breast cancer. *N Engl J Med*. 2002;347(16):1227-32.
2. Fisher B, Jeong JH, Anderson S, Bryant J, Fisher ER, Wolmark N. Twenty-five-year follow-up of a randomized trial comparing radical mastectomy, total mastectomy, and total mastectomy followed by irradiation. *N Engl J Med*. 2002;347(8):567-75.
3. Jeevan R, Cromwell DA, Trivella M, Lawrence G, Kearins O, Pereira J, et al. Reoperation rates after breast conserving surgery for breast cancer among women in England: retrospective study of hospital episode statistics. *BMJ*. 2012;345:e4505.
4. McCahill LE, Single RM, Aiello Bowles EJ, Feigelson HS, James TA, Barney T, et al. Variability in reexcision following breast conservation surgery. *JAMA*. 2012;307(5):467-75.
5. Urban C, Lima R, Schunemann E, Spautz C, Rabinovich I, Anselmi K. Oncoplastic principles in breast conserving surgery. *Breast*. 2011;20(Suppl 3):S92-5.
6. Kuhl CK, Schrading S, Leutner CC, Morakkabati-Spitz N, Wardelmann E, Fimmers R, et al. Mammography, breast ultrasound, and magnetic resonance imaging for surveillance of women at high familial risk for breast cancer. *J Clin Oncol*. 2005;23(33):8469-76.
7. Kriege M, Brekelmans CT, Boetes C, Besnard PE, Zonderland HM, Obdeijn IM, et al. Efficacy of MRI and mammography for breast-cancer screening in women with a familial or genetic predisposition. *N Engl J Med*. 2004;351(5):427-37.
8. Kuhl C, Weigel S, Schrading S, Arand B, Bieling H, Konig R, et al. Prospective multicenter cohort study to refine management recommendations for women at elevated familial risk of breast cancer: the EVA trial. *J Clin Oncol*. 2010;28(9):1450-7.

9. Fischer U, Kopka L, Grabbe E. Breast carcinoma: effect of preoperative contrast-enhanced MR imaging on the therapeutic approach. *Radiology*. 1999;213(3):881-8.
10. Lehman CD, Blume JD, Weatherall P, Thickman D, Hylton N, Warner E, et al. Screening women at high risk for breast cancer with mammography and magnetic resonance imaging. *Cancer*. 2005;103(9):1898-905.
11. Fischer U, Zachariae O, Baum F, von Heyden D, Funke M, Liersch T. The influence of preoperative MRI of the breasts on recurrence rate in patients with breast cancer. *Eur Radiol*. 2004;14(10):1725-31.
12. Mann RM, Loo CE, Wobbes T, Bult P, Barentsz JO, Gilhuijs KG, et al. The impact of preoperative breast MRI on the re-excision rate in invasive lobular carcinoma of the breast. *Breast Cancer Res Treat*. 2010;119(2):415-22.
13. Turnbull L, Brown S, Harvey I, Olivier C, Drew P, Napp V, et al. Comparative effectiveness of MRI in breast cancer (COMICE) trial: a randomised controlled trial. *Lancet*. 2010;375(9714):563-71.
14. Peters NH, van Esser S, van den Bosch MA, Storm RK, Plaisier PW, van Dalen T, et al. Preoperative MRI and surgical management in patients with nonpalpable breast cancer: the MONET - randomised controlled trial. *Eur J Cancer*. 2011;47(6):879-86.
15. Kuhl C, Kuhn W, Braun M, Schild H. Pre-operative staging of breast cancer with breast MRI: one step forward, two steps back? *Breast*. 2007;16(Suppl 2):S34-44.
16. Saslow D, Boetes C, Burke W, Harms S, Leach MO, Lehman CD, et al. American Cancer Society guidelines for breast screening with MRI as an adjunct to mammography. *CA Cancer J Clin*. 2007;57(2):75-89.
17. Sardanelli F, Boetes C, Borisch B, Decker T, Federico M, Gilbert FJ, et al. Magnetic resonance imaging of the breast: recommendations from the EUSOMA working group. *Eur J Cancer*. 2010;46(8):1296-316.
18. Bleicher RJ, Ciocca RM, Egleston BL, Sesa L, Evers K, Sigurdson ER, et al. Association of routine pretreatment magnetic resonance imaging with time to surgery, mastectomy rate, and margin status. *J Am Coll Surg*. 2009;209(2):180-7; quiz 294-5.
19. Pengel KE, Loo CE, Teertstra HJ, Muller SH, Wesseling J, Peterse JL, et al. The impact of preoperative MRI on breast-conserving surgery of invasive cancer: a comparative cohort study. *Breast Cancer Res Treat*. 2009;116(1):161-9.
20. Van Goethem M, Schelfout K, Dijckmans L, Van Der Auwera JC, Weyler J, Verslegers I, et al. MR mammography in the pre-operative staging of breast cancer in patients with dense breast tissue: comparison with mammography and ultrasound. *Eur Radiol*. 2004;14(5):809-16.
21. Houssami N, Ciatto S, Macaskill P, Lord SJ, Warren RM, Dixon JM, et al. Accuracy and surgical impact of magnetic resonance imaging in breast cancer staging: systematic review and meta-analysis in detection of multifocal and multicentric cancer. *J Clin Oncol*. 2008;26(19):3248-58.
22. Sardanelli F, Giuseppetti GM, Panizza P, Bazzocchi M, Fausto A, Simonetti G, et al. Sensitivity of MRI versus mammography for detecting foci of multifocal, multicentric breast cancer in fatty and dense breasts using the whole-breast pathologic examination as a gold standard. *AJR Am J Roentgenol*. 2004;183(4):1149-57.
23. Plana MN, Carreira C, Muriel A, Chiva M, Abaira V, Empananza JI, et al. Magnetic resonance imaging in the preoperative assessment of patients with primary breast cancer: systematic review of diagnostic accuracy and meta-analysis. *Eur Radiol*. 2012;22(1):26-38.
24. Lim HI, Choi JH, Yang JH, Han BK, Lee JE, Lee SK, et al. Does pre-operative breast magnetic resonance imaging in addition to mammography and breast ultrasonography change the operative management of breast carcinoma? *Breast Cancer Res Treat*. 2010;119(1):163-7.
25. Gurdal SO, Ozcinar B, Kayahan M, Igci A, Tunaci M, Ozmen V, et al. Incremental value of magnetic resonance imaging for breast surgery planning. *Surg Today*. 2013;43(1):55-61.
26. Fan XC, Nemoto T, Blatto K, Mangiafesto E, Sundberg J, Chen A, et al. Impact of presurgical breast magnetic resonance imaging (MRI) on surgical planning - a retrospective analysis from a private radiology group. *Breast J*. 2013;19(2):134-41.
27. Lehman CD, Gatsonis C, Kuhl CK, Hendrick RE, Pisano ED, Hanna L, et al. MRI evaluation of the contralateral breast in women with recently diagnosed breast cancer. *N Engl J Med*. 2007;356(13):1295-303.
28. Killelea BK, Long JB, Chagpar AB, Ma X, Soulos PR, Ross JS, et al. Trends and clinical implications of preoperative breast MRI in Medicare beneficiaries with breast cancer. *Breast Cancer Res Treat*. 2013;141(1):155-63.
29. Miller BT, Abbott AM, Tuttle TM. The influence of preoperative MRI on breast cancer treatment. *Ann Surg Oncol*. 2012;19(2):536-40.
30. Schell AM, Rosenkranz K, Lewis PJ. Role of breast MRI in the preoperative evaluation of patients with newly diagnosed breast cancer. *AJR Am J Roentgenol*. 2009;192(5):1438-44.
31. Houssami N, Hayes DF. Review of preoperative magnetic resonance imaging (MRI) in breast cancer: should MRI be performed on all women with newly diagnosed, early stage breast cancer? *CA Cancer J Clin*. 2009;59(5):290-302.
32. Houssami N, Turner R, Morrow M. Preoperative magnetic resonance imaging in breast cancer: meta-analysis of surgical outcomes. *Ann Surg*. 2013;257(2):249-55.
33. Houssami N, Turner R, Macaskill P, Turnbull LW, McCready DR, Tuttle TM, et al. An individual person data meta-analysis of preoperative magnetic resonance imaging and breast cancer recurrence. *J Clin Oncol*. 2014;32(5):392-401.
34. Katipamula R, Degnim AC, Hoskin T, Boughey JC, Loprinzi C, Grant CS, et al. Trends in mastectomy rates at the Mayo Clinic Rochester: effect of surgical year and preoperative magnetic resonance imaging. *J Clin Oncol*. 2009;27(25):4082-8.
35. Morrow M, Harris JR, Schnitt SJ. Surgical margins in lumpectomy for breast cancer--bigger is not better. *N Engl J Med*. 2012;367(1):79-82.
36. Graphpad Prism for Windows. GraphPad Software. San Diego, California, USA. [cited 2014 May 23]. Available from: <http://www.graphpad.com>
37. Zar JH. *Biostatistical analysis*. 5. ed. USA: Prentice Hall;2009.